

## Hereditary Kidney Disease in Dogs

Catherine A. Picut, VMD  
Diplomate, ACVP  
Senior Pathologist  
Veritas Laboratories, Inc.  
Burlington, North Carolina

Robert M. Lewis, DVM  
Professor of Pathology  
New York State College of  
Veterinary Medicine  
Cornell University  
Ithaca, New York

Catherine Ann Picut received the VMD degree from the University of Pennsylvania School of Veterinary Medicine. She completed her residency in anatomic pathology at the New York State College of Veterinary Medicine and is board certified by the American College of Veterinary Pathologists.

Robert Miller Lewis holds a DVM degree from Washington State University. Dr. Lewis is a professor of pathology at the New York State College of Veterinary Medicine, where he served as chairman of the department from 1973 to 1985.

### DEFINITIONS

chies) in dogs are diseases of the kidney (nephropathies).

plex clinicopathological entities, many of which cause renal failure and uremia in dogs. These diseases are considered to be genetically based because of the familial occurrence in certain breeds, the development of disease early in life, and the consistency of lesions in patient populations. Although some are not observed clinically, most cause clinical signs that progress during juvenile and adolescent years. In most instances, the disease is present at birth (i.e., congenital) even though clinical renal failure is not apparent until the animal is several months old.

Kidney diseases believed to have a genetic basis have been described in 15 breeds (Table 1). These disorders cover a spectrum of functional and structural defects, including the absence of a kidney (agenesis), the abnormal development of a kidney (dysplasia), cystic disease, disorder of glomerulus (glomerulopathy), disorder of tubules and/or parenchyma between tubules (tubulo-interstitial nephropathy), or abnormal resorption and/or excretion of solutes by tubules (tubular transport dysfunction) (Figure 1).

Aside from agenesis and tubular transport dysfunction, the history, clinical signs, and clinical pathology of the other disorders are comparable with and characteristic of chronic renal failure. None of these disorders is limited to the breeds mentioned, however. Sporadic cases of each disorder can occur in any breed of dog without obvious familial predisposition.

This discussion of hereditary kidney diseases in dogs will highlight the specific features and comparative pathology of the recognized hereditary kidney diseases. Because chronic renal failure (CRF) is the most common clinical presentation of hereditary kidney disease, it will be reviewed first by breed predispositions.

### NEPHROPATHIES IN VARIOUS BREEDS OF DOGS

#### Beagle

The absence of one kidney (unilateral renal agenesis) has been reported in seven Beagles from one breeding colony and in two other related Beagles. In addition to these two reports, the incidence of this disease in some Beagle colonies can be as high as one in one hundred. This disorder is presumed to have a genetic basis; however, breeding trials have

- ' agenesi—failure in development (as of a body part)
- ° dysplasia—abnormal growth or development of the organs
- ' nephropathy—an abnormal state of the kidney
- ° pathogenesis—the development of disease or the events and reactions of the disease

not been performed to determine the mode of inheritance. Unilateral renal agenesis can occur in either males or females, and is commonly associated with other abnormalities of the urinary or genital tracts, including cryptorchidism (a condition in which one or both testes fail to descend normally), hypospadias (abnormality of the penis in which the urethra opens on the undersurface), and contralateral renal dysplasia (which affects the opposite kidney).

The absence of one kidney usually does not cause clinical problems in the individual animal, although the remaining kidney enlarges to compensate for the loss. This disorder may go unnoticed or may be discovered accidentally during abdominal radiographs taken of the animal for another problem. Conversely, if contralateral renal dysplasia exists, renal failure ensues at an early age.

**Lhasa Apso and Shih Tzu**  
Hereditary renal disease in the Lhasa Apso and in the Shih Tzu is clinicopathologically similar and is characterized as renal dysplasia. Fetal dysplasia is probably the most commonly encountered renal disease in these two breeds. This disorder may affect males or females and is carried in the genes as a recessive trait without sex predilection.

Affected dogs present with clinical signs of renal failure prior to one year of age, and rapidly decline to death. Elevated blood urea nitrogen and creatinine levels (azotemia) and a fixed (unchanged) specific gravity of urine are consistent findings. An excess of serum proteins in the urine (proteinuria) and blood in the urine (hematuria) occasionally are additional findings of urinalysis.

The cause of renal dysplasia is unknown, but it probably results from a defect in embryological development. Renal dysplasia usually is present at birth; however, affected animals do not show

### I-Hereditarily Kidney Disease in Dogs

Disorder ; = Clinical Features

Agenesis of one kidney  
Dysplasia of the remaining kidney

Chronic renal failure

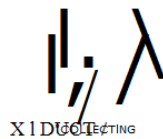
Cystic Disease

Glomerulopathy - I'

Tubulo-Interstitial'

Tubular Transp

Tubular Transp " x



signs of renal failure until they are at least two months old. The earliest changes in the kidney are, therefore, infrequently examined.

Consequently, the progression of this disease is poorly understood by pathologists. By the time the patients develop renal failure, the kidneys are usually end-stage (i.e., shrunken, pale, firm, irregularly indented) (Figure 2). Small, 1- to 2-mm fluid-filled cysts can be observed in the cortex or medulla. These kidneys cannot be distin-

Figure 1. Schematic of nephron comprised of glomerulus, tubule, and collecting duct. Arrows indicate normal flow of urine.

guished grossly from kidneys of older dogs with chronic renal disease; dysplasia can be recognized by histopathological examination, which charts the tissue changes characteristic of disease.

Histopathological diagnosis is difficult because features of dysplasia are usually obscured by an

abundance of fibrosis and by mild inflammation. The pathological diagnosis, therefore, may be "chronic interstitial nephritis." The astute pathologist, clinician, and breeder will strongly suspect this hereditary renal disease (i.e., dysplasia) given the appropriate breed and young age of the animal.

Figure 2. End-stage kidney from a two-month-old Shih Tzu with renal dysplasia. (A) Kidney is irregularly indented and shrunken. The capsule is thickened and firmly adherent. (B) On cut section, small cysts are present in the cortex and medulla. The thin cortex is typical of renal dysplasia.

**Soft-coated Wheaten Terrier and Standard Poodle**  
Renal dysplasia in families of soft-coated Wheaton Terriers and Standard Poodles has been reported. Affected animals between 1 and 30 months of age with renal failure exhibited no obvious sex predilection. Breeding trials have not been performed to establish the mode of inheritance. The clinical presentation, urinalysis, and pathological findings are similar to those in Lhasa Apsos and Shih Tzus with renal dysplasia.

**Cooker Spaniel**  
A rapidly progressive renal disease with a clinical onset between

thin (Figure 4). Viewed under a microscope (histopathologically), there is a decreased number of nephrons. Whether this condition should be referred to accurately as hypoplasia is controversial, because some histopathological changes are more consistent with a glomerulopathy or with a tubulointerstitial nephropathy. This argument may be academic, however, because for clinicians or breeders, it is sufficient to recognize this entity as a cause of renal failure and death in young Cooker Spaniels and to realize this condition can be controlled only by breeding management. The incidence of this disease has been on the decline

this disease is still tentative, it has been suggested that the disease is carried in the genes as a recessive trait. In contrast to the diseases described in other breeds, this kidney disease is typified by kidneys that are larger than normal. Multiple large, fluid-filled cysts occupy the cortex and medulla, hence the term "polycystic kidney disease." Extensive clinical information about the progression of this disease is not available; however, the few reported patients had an onset of renal failure at six weeks of age. When this disease is suspected based upon the clinical presentation and upon the gross pathology of the kidneys, it is important to ex-

six months and two years of age is over the past ten years.

recognized in Cooker Spaniels. There is no sex predilection and the pattern of inheritance is questionable. As with renal dysplasia of Lhasa Apsos and Shih Tzus, affected Cooker Spaniels present with dehydration, a fixed specific gravity of urine, proteinuria, and occasionally glucose and/or blood in the urine.

This hereditary renal disease has been referred to as hypoplasia, which literally means a decreased mass of the kidney. The kidneys are small and contracted, indistinguishable from an end-stage kidney resulting from any other disease (Figure 3). When the organ is cut, the cortex is very

#### Keeshond and Bedlington Terrier

A limited number of reports in the literature deal with advanced kidney disease in young Keeshonds and Bedlington Terriers. End-stage kidney disease and the clinical presentation of chronic renal failure were noted in related dogs

of these two breeds, but the underlying defect and mode of inheritance are unknown.

#### Cairn Terrier

In 1980, a familial and congenital primary cystic kidney disease was reported in Cairn Terriers. Although the hereditary nature of

amine the liver histopathologically. Characteristic lesions in the liver have been associated with this kidney disease, namely portal fibrosis and bile duct proliferation.

#### Samoyed

Perhaps the best described hereditary kidney disease is the glomerulopathy of the Samoyed breed. A great deal of attention has been paid to understanding the development and pathogenesis of this kidney disease. Because the disease is an X-linked dominant disease, males are more frequently affected than females. Hereditary kidney disease in Samoyeds is considered an animal version of the human disease known

as hereditary nephropathy because of the genetic, clinical, and pathological similarities between the two diseases.

In male dogs, the disease is more severe and occurs at an earlier age. The earliest clinical indication of disease is proteinuria at two months of age. Rapid progression to death occurs by 16 months. Urinalysis reveals a specific gravity in the range of 1.012 to 1.025 g/ml with consistent proteinuria and glucosuria (glucose in the urine). Occasionally, blood in the urine (hematuria) and gelled protein in the urine (urinary casts) are noted.

Female dogs experience a mild form of this disease and may only demonstrate mild, persistent proteinuria and no other clinical signs. Onset of histopathological changes begins between six months and five years; changes may not be evident until five years of age.

The underlying defect of the kidney lies in the basement membrane of the glomerulus, which is the blood-filtering unit of the neph-

rocyte. The surface is finely pitted and coarsely granular.

These changes are similar to those that occur in the more commonly encountered disease called immune-complex glomerulonephritis (ICGN), which is characterized by destruction of and inflammation of the glomerulus caused by the animal's own antibodies. End-stage kidneys are unusual. A histopathological report may indicate membranoproliferative glomerulonephritis or glomerulosclerosis. With light microscopy alone, it is not possible to distinguish the Samoyed nephropathy from the acquired ICGN of multiple breeds. This distinction would require electron microscopy and/or immunopathology. Histopathological changes in a young Samoyed should, however, place the diagnosis of hereditary nephropathy first on the list.

#### Doberman Pinscher

A familial glomerulopathy is well characterized in the Doberman Pinscher. This hereditary kidney disease is similar to the glomer-

#### Hereditary Kidney Disease 5

ular failure can occur any time between six weeks and eight years of age. Urinalyses include proteinuria, casts, glucosuria, and hematuria.

The underlying disease process is poorly understood. The disease is believed to represent a primary glomerulopathy. Grossly, the kidneys are normal or slightly reduced in size. The surface of the cortex is mottled yellow to brown and is coarsely granular (Figure 5). Under light microscopy, the lesion represents a membranoproliferative glomerulonephritis, indistinguishable from that caused by immune-complex glomerulonephritis (ICGN). In the Doberman Pinscher, differentiation of familial glomerulopathy from ICGN is difficult and requires immunopathological methods and/or electron microscopy.

#### Norwegian Elkhound

A primary tubulo-interstitial nephropathy with a familial basis is recognized in Norwegian Elkhounds. Although lesions visible under light microscopy can be de-

ron. Extensive immunological and biochemical analyses of the basement membrane reveal a defect in production of an important structure in this membrane. The primary disorder is within the glomerulus, so this entity is classified as a glomerulopathy. Grossly, the kidneys are of normal size with a

ulopathy in the Samoyed, with a few notable differences. The hereditary nature of the disease is poorly understood. Although there is no sex predilection, males appear to be affected more severely and at an earlier age (mean age, 21 months) than females (mean age, 30 months). The onset of clin-

tected as early as three months of age, clinical illness does not occur until between eight months and five years of age. Urine from affected dogs has a specific gravity fixed at 1.008 to 1.012 g/ml (isosthenuria) with occasional proteinuria, glucosuria, and an excess of amino acids in the urine (ami-

Figure 3. End-stage kidney from a young dog with congenital kidney disease. (A) Kidney is pale with an irregularly indented surface. A small cyst is visible on the surface. (B) On cut section, the cortex is extremely thin compared with the medulla.

6 Pedigree Forum

noaciduria). As with the majority of the other hereditary kidney diseases in dogs, the mode of inheritance is not clear.

The underlying disorder is believed to reside in the tubules. Although the kidneys are normal at birth, with time, advancing interstitial fibrosis leads to the typical appearance of end-stage kidneys. The expected histopathological diagnosis is either chronic interstitial nephritis or diffuse interstitial fibrosis. Inflammation is not a prominent feature of the lesion. Again, the distinction is made between this disorder and chronic end-stage renal disease of older dogs based upon the age and breed of the patient.

A second renal disease with a presumed genetic basis has been described recently in the Norwegian Elkhound. This condition is a tubular transport defect for glu-

The underlying defect is believed to reside in the membrane structure or in the metabolism of the tubular cells leading to

COHTEX

URETEFI

Figure 4. Schematic of canine kidney on cut section, showing cortex, medulla, pelvis, and ureter.

This defect is specific for the amino acid cystine, unlike the generalized transport defect in the Basenji breed. In Irish Terriers, a sex-



cose, resulting in high levels of glucose in the urine (glucosuria). Primary glucosuria is clinically unimportant. When recognized on routine urinalysis, however, breeding management may be recommended.

#### Basenji

A hereditary tubular transport defect exists in the Basenji and serves as an animal model of the Fanconi syndrome in humans.

Clinical signs, appearing between one and six years of age, include an increased quantity of urine (polyuria), increased thirst (polydipsia), dehydration, vomiting, and weight loss. Acidosis, an abnormal condition characterized by reduced alkalinity of the blood and of the body tissues, is a representative and consistent finding. Patients may progress rapidly to death or may stabilize for several years. Urinalyses reveal a low (1.001 g/ml) to fixed specific gravity, glucosuria, and aminoaciduria.

There is loss of acidic, basic, and/or neutral amino acids because there is abnormal transport of these substances across the tubules.

loss of water, glucose, phosphorus, sodium, potassium, urate, and amino acids into the urine. An important distinction between this disease and other canine renal diseases is that blood urea nitrogen and creatinine are not elevated characteristically. These waste products are cleared readily from the blood because glomerular filtration is not compromised.

Unlike the hereditary kidney diseases discussed above, the primary abnormality in the Basenji is functional with little apparent structural alteration. Grossly, the kidneys are relatively normal. Necrosis of the renal crest may be observed secondary to dehydration and acidosis. The lesions visible under light microscopy are variable and often subtle. Large tubular epithelial cells with enlarged dark nuclei is perhaps the one characteristic finding. Varying degrees of chronic interstitial nephritis may be the only histopathological diagnosis reported.

#### Irish Terrier

As in the Basenji, a primary renal tubular transport defect has been recognized in Irish Terriers.

linked trait is suspected because the condition is seen primarily in male dogs. Diagnosis is based on the presence of cystine in the urine (cystinuria) despite normal cystine levels in the blood. The disease is insignificant clinically except for the fact that high levels of cystine in the urine can lead to the formation of cystine stones (uroliths). These cystine uroliths can block the ureter and urethra, leading to lower urinary tract obstruction and ascending bacterial infections.

#### Dalmatian

A genetically-linked tubular transport defect for uric acid has long been recognized in the Dalmatian. Historically, this defect represents the first hereditary kidney disease described in dogs. Defective transport of uric acid across all cell membranes including kidney and liver cells, combined with reduced activity of the enzyme uricase lead to elevated levels of uric acid in the blood and urine.

As in Irish Terriers with cystinuria, this condition in Dalmatians is clinically silent except for the

predisposition to stone formation in the lower urinary tract. Interestingly, the incidence of urolith formation does not correlate with the degree of uric acid in the urine; therefore, other factors must play a role in uric acid stone formation. Stones usually first develop between three and six years of age and affected animals present with lower urinary tract infections. Surgical removal of stones followed by medical management with allopurinol, a xanthine oxidase inhibitor, have proven effective in treating this condition and preventing the recurrence of stones.

#### CLINICAL PRESENTATION

Before discussing the clinical

failure associated with hereditary disease from renal failure associated with a variety of other causes. Patients usually present with a rapid onset of clinical signs, even though the disease has been present for quite some time (months). Owners will report the following: polyuria, polydipsia, loss of appetite (anorexia), depression, malaise, vomiting, and diarrhea.

Upon physical examination, common findings include fetid breath (halitosis), ulcers on the gums and tongue, pallor (anemia), dehydration, and especially in immature dogs, loose teeth and stunted growth (osteodystrophy).

#### CLINICAL PATHOLOGY

#### Hereditary Kidney Disease 7

be quite diagnostic for chronic renal failure. Blood urea nitrogen (BUN) and creatinine are elevated. For BUN, values in excess of 150 to 200 mg/dl are not uncommon. Creatinine will increase fourfold, up to 4 to 6 mg/dl with functional loss of 75% of the kidney mass. Elevated phosphorous levels also support renal failure. Caution must be exercised when evaluating phosphorous values in young dogs because normal puppies can have values as high as 5 to 8 mg/dl.

Electrolyte, protein, and fluid disturbances typical of acute renal failure are not characteristic of chronic renal failure resulting from hereditary kidney disease. This is because in chronic conditions,

presentation of dogs with hereditary renal disease, it is important to draw a distinction between renal disease and renal failure. Renal disease represents any degree of structural or functional abnormality in the kidney. It may be mild and self-limiting or may be extensive and progressive; resulting in terminal renal failure. Renal agenesis and tubular transport defects may represent renal disease, even though they infrequently result in renal failure. Renal failure refers to the complex symptomatology of multiple organ malfunction, which is attributed to some forms of renal disease. Frequently, renal failure is used interchangeably with the term uremia, which literally means "urine in the blood."

In general, the clinical presentation of dogs with most forms of hereditary renal disease is characteristic of chronic renal failure. The signs include dysplasia, glomerulopathy, and tubulo-interstitial nephropathy of certain breeds described above. Because these conditions are more commonly encountered than other conditions, the remainder of this discussion will focus on the clinical presentation of renal failure associated with these three types of hereditary disease.

There are no unique clinical signs that can distinguish renal

#### Hematology

A complete blood count (CBC) alone is not diagnostic for chronic renal failure, but certain findings will support such a diagnosis. A low-grade normochromic, normocytic anemia frequently exists. Packed cell volume (PCV), red blood cell (RBC) count, and total hemoglobin are low, indicating a decreased number of red blood cells. Individual RBC morphology remains normal.

#### Clinical Chemistry

The clinical chemistry profile can

compensatory mechanisms attempt to maintain normal blood calcium, normal pH, and normal protein levels.

#### Urinalysis

Aside from clinical chemistry findings, the urinalysis will provide valuable information for diagnosing chronic renal failure. Typically, the urine will be dilute with a fixed specific gravity of 1.008 to 1.010 g/ml, which is similar to that of the fluid initially filtered from the blood (glomerular ultrafiltrate). The finding of dilute urine is particularly

Figure 5. Kidney from a 3-month-old Doberman Pinscher. The mottled surface is characteristic of glomerulopathy. Note the difference between the gross appearance of this kidney and the end-stage kidney typical of dysplasia (see Figure 3).

meaningful in a clinically dehydrated patient because it indicates that the kidney tubules cannot concentrate urine to preserve body fluid.

Additional findings may be mild to moderate proteinuria and hyaline casts. Any disease process that affects the glomerulus (i.e., the structure that initially filters the

deposits in the stomach, lungs, and kidney are readily apparent on radiographs. Malformed long bones with widened metaphyses, loss of lamina dura around teeth, and general loss of radiographic density of all bones are indicative of renal osteodystrophy. CRF in young, rapidly growing dogs is commonly associated with remark-

ined incompletely in many instances. Recognition of the disorder and proper breeding management are the only means of eliminating the genetic trait from canine populations. Treatment is generally palliative and directed toward alleviating the signs of renal failure. There is no treatment to reverse the underlying disease process. Veterinarians must be aware of and recognize these conditions so that breeding management can be instituted properly.

recognized in many breeds of dogs and are significant causes of renal failure in young dogs.

blood to form urine) can lead to leakage of blood protein into the urine. This protein may precipitate in the tubules to form casts, which may be evident in the collected urine.

#### DIAGNOSIS

When veterinarians are presented with young purebred dogs with clinical signs and clinical pathology supportive of chronic renal failure, hereditary renal disease should be high on the list of differential diagnoses. Questioning the owner as to illness or early death in related dogs may uncover useful information. Additional diagnostic measures include radiographs and kidney biopsy.

#### Radiographs

Abdominal radiographs are useful for examining the size and shape of the kidneys. Normally, each kidney should be 2.5 to 3.5 times the length of the second lumbar vertebra. In the hereditary diseases characterized by end-stage kidneys, the kidneys will be small and irregularly shaped. Soft tissue calcification and osteodystrophy are characteristic features of chronic renal disease. Mineral

able bone changes, compared with CRF of old dogs.

#### Kidney Biopsy

An open wedge or keyhole needle biopsy of the kidney is recommended early in the course of disease to determine the extent of renal disease and to monitor the progression of the disease. Unfortunately, the patients usually present in advanced stages of disease and kidney biopsy often does little but confirm end-stage kidney disease. Nevertheless, this procedure is important to help rule out infectious diseases such as bacterial pyelonephritis or leptospirosis, which can respond to antibiotic therapy. Depending on the histopathological diagnosis, immunofluorescence may be warranted to rule out immune-complex mediated glomerulonephritis.

#### SUMMARY

Hereditary kidney diseases have been recognized in many breeds of dogs and are significant causes of renal failure in young dogs. A wide diversity of structural and/or functional defects accounts for the clinicopathological entities. The mode of inheritance has been de-

#### BIBLIOGRAPHY

- Bovee KC: Genetic and metabolic disease of the kidney, in Bovee KC (ed): *Canine Nephrology*. Philadelphia, Harwal Publishing Co, 1984, pp 339-354.
- Chew DJ, DiBartola SP, Boyce JT, Hayes KM, Brace JJ: Juvenile renal disease in Doberman Pinscher dogs. *JAVMA* 182:481-485, 1983.
- Eriksen K, Grondalen J: Familial renal disease in soft-coated Wheaten Terriers. *J Sm Anim Pract* 25:489-500, 1984.
- Finco DH: Familial renal disease in Norwegian Elkhound dogs: physiologic and biochemical examination. *Am J Vet Res* 37:87-91, 1976.
- Jansen B, Tryphonas L, Wong J, et al: Mode of inheritance of Samoyed hereditary glomerulopathy: an animal model for hereditary nephritis in humans. *J Lab Clin Invest* 107:551-555, 1984.
- Jubb KVH, Kennedy PC, Palmer N: The urinary system: anomalies of development, in *Pathology of Domestic Animals*. New York, Academic Press, 1985, pp 350-356.
- Lucke VM, Kelly DF, Darke PG, Gaskell CJ: Chronic renal failure in young dogs—possible renal dysplasia. *J Sm Anim Pract* 21:169-181, 1980.
- McKenna SC, Carpenter JL: Polycystic disease of the kidney and liver in the Cairn Terrier. *Vet Pathol* 17:436-442, 1980.
- O'Brien TD, Osborne CA, Yano BL, Baines DM: Clinicopathologic manifestations of progressive renal disease in Lhasa Apso and Shih Tzu dogs. *JAVMA* 180:1658-664, 1982.
- Picut CA, Lewis RM: Microscopic features of canine renal dysplasia. *Vet Pathol* 24:156-163, 1986.
- Picut CA, Lewis RM: Comparative pathology of canine hereditary nephropathies: an interpretive review. *Vet Res Commun* 11(6):561-581, 1987.
- Steward AP, Macdougall DF: Familial nephropathy in the Cocker Spaniel. *J Sm Anim Pract* 24:15-24, 1984.